

Percutaneous Sclerotherapy for Vascular Malformations – A systematic review

SL Gurgacz¹, L Zamora¹ and GJ Maddern^{1,2}

- 1 Australian Safety and Efficacy Register of New Interventional Procedures – Surgical (ASERNIP-S), Royal Australasian College of Surgeons
- 2 Department of Surgery, The Queen Elizabeth Hospital and University of Adelaide

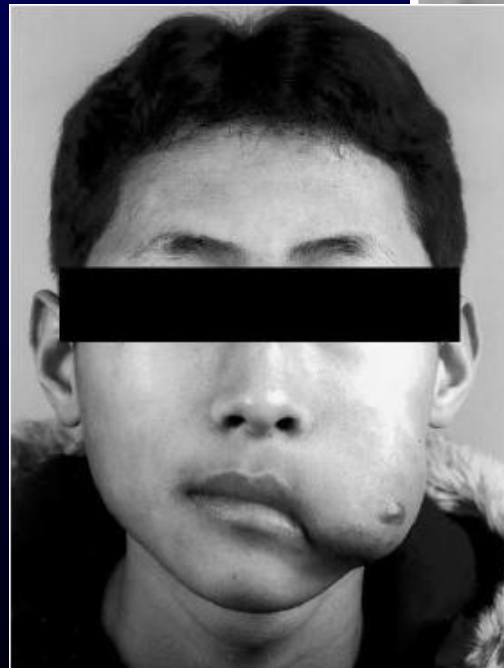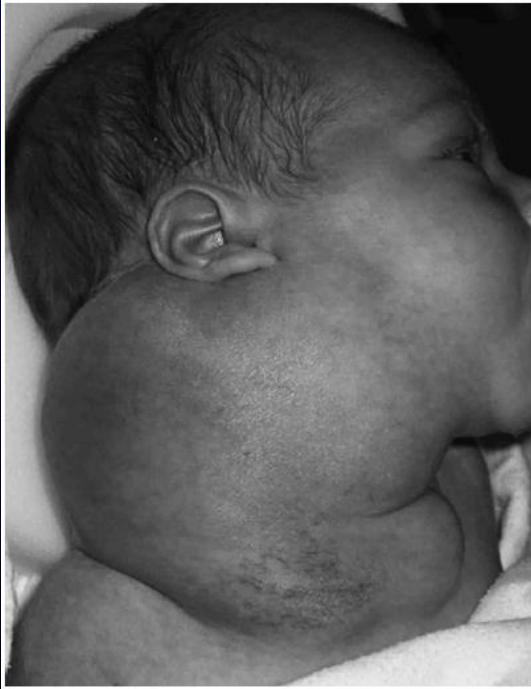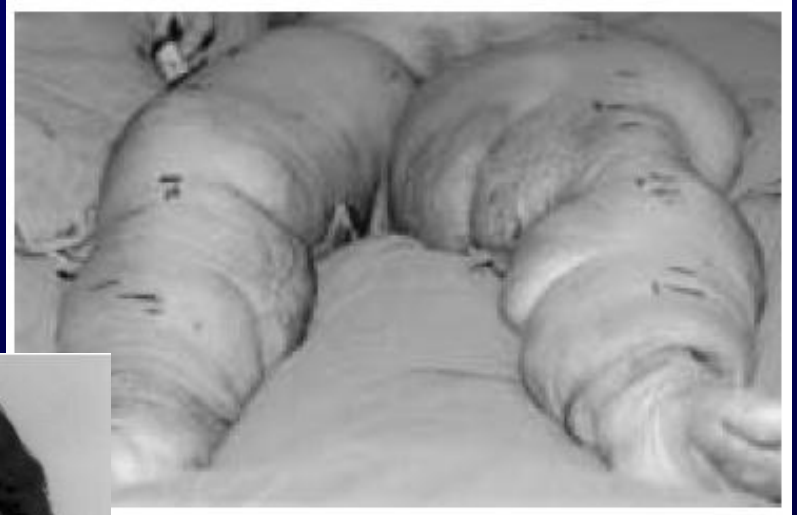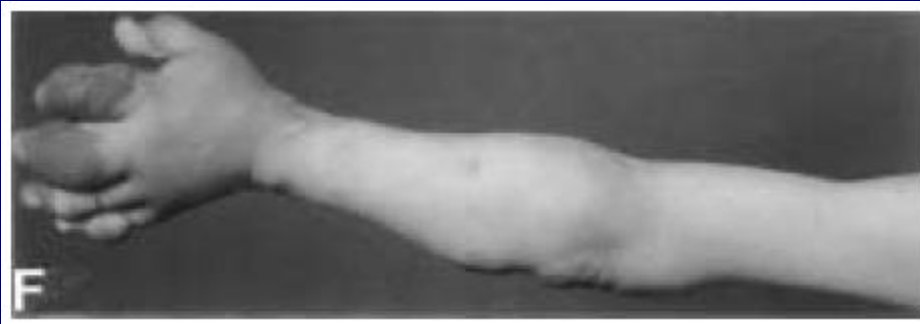


Background

- Sclerotherapy aims to eradicate or reduce abnormal vasculature with minimal invasiveness.
- Advances in the percutaneous sclerotherapy (PS) technique due to:
 - high recurrence rates
 - poor symptomatic improvement
 - poor cosmetic improvementwhen lesions are surgically excised.



Vascular Malformations



Aim

To determine the safety and efficacy of percutaneous sclerotherapy for patients with congenital vascular malformations via review of current peer reviewed literature.



Methods

- Literature was identified via systematic searches of electronic databases
- Only recently published (year 2000 onwards) peer reviewed publications with a minimum of 20 patients were included.



Results

- A total of 17 articles were included for review:
 - 1 systematic review
 - 1 RCT
 - 15 case series.
- Venous malformations (VMs) comprised almost half of the patient population, followed by lymphatic malformations (LMs), arteriovenous malformations (AVMs), arteriovenous fistulae (AVFs) and mixed malformations.



Results

- Ethanol was the most commonly used sclerosant, with all venous malformations treated with this agent.
- Lymphatic malformations were treated with OK-432, doxycycline and STS.



Safety

- The total number of adverse events reported amongst the 15 studies (1027 patients) included was at least 369, including systemic and localised complications.
- Majority resolved without further intervention.



Safety

- Patients with venous malformations experienced a greater range of acute systemic and localised complications
 - transient pulmonary hypertension
 - transient oxygen desaturation
 - haematuria
 - nerve palsy
 - muscle atrophy and
 - skin necrosis



Safety

- In contrast, complications involving lymphatic malformations appeared to be more localised in nature
 - prolonged pain
 - oedema
 - skin blistering
 - infection



Efficacy - Venous malformations

- 8 studies reported the efficacy of percutaneous sclerotherapy for venous malformations.
- In 5 of the 8 studies majority of patients achieved fair to poor lesion response.
- Only 2 studies reported lesion recurrence, which occurred in 4 of 119 patients.



Efficacy - Lymphatic malformations

- Four studies included in the efficacy analysis for LMs.
- Three utilising OK-432 and 1 study doxycycline.
- All studies reported > 50% of patients achieved a minimum of good lesion response.
- In the 3 studies using OK-432 most patients achieved good to complete lesion regression.



Efficacy – Venous and lymphatic

- 1 study reported the lesion regression for venous malformations and lymphatic malformations.
- 80% of lymphatic malformations achieved a good response.
- 90% of venous malformations only achieved fair/poor lesion response.



AVF, non-AVF and mixed lesions

- Only 1 study included.
- Majority of patients achieved good or complete lesion regression.
- Majority of patients with high flow lesions achieved complete lesion regression (13/16 patients, 81 percent).
- Patients with low flow lesions achieved good lesion regression (12/24 patients, 50 percent)



Conclusions

- Clinical effectiveness of percutaneous sclerotherapy may be dependant on proper patient selection:
 - due to the large variability in lesion and treatment complexity.
- Lesion architecture and histology was a determining factor of patient outcomes, particularly for mixed venous and microcystic lymphatic malformations.



Conclusions

- Clinical outcomes appeared to benefit from a multi-disciplinary team approach
 - Patient selection
 - Type of procedure undertaken
 - Anaesthetic support



Future directions


- Case series will continue to constitute the best available evidence
 - Vascular malformations are rare
 - Lack of suitable comparator
- Highlights the need for well designed case series
 - Multiple data points
 - Well documented patient/lesion characteristics
 - Standardised outcomes
 - Members of clinical treatment team reported



Acknowledgements

- The Victorian Department of Human Services
- Dr Stephen Fasulakis
- Dr Winston Chong
- Dr James Burnes





The End

Image courtesy of Dr Randall Sach